

Residual Visual Responses in Patients With Retinitis Pigmentosa Revealed by Functional Magnetic Resonance Imaging

Elisa Castaldi¹, Guido Marco Cicchini², Benedetto Falsini³, Paola Binda^{2,4}, and Maria Concetta Morrone^{4,5}

¹ Department of Neuroscience, Psychology, Pharmacology and Child Health, University of Florence, Florence, Italy

² Institute of Neuroscience CNR, Pisa, Italy

³ Department of Ophthalmology, Policlinico Gemelli, Università Cattolica del Sacro Cuore, Rome, Italy

⁴ Department of Translational Research and New technologies in Medicine and Surgery, University of Pisa, Pisa, Italy

⁵ IRCCS Stella Maris, Calambrone, Pisa, Italy

Correspondence: Maria Concetta Morrone, Department of Translational Research on New Technologies in Medicine and Surgery, University of Pisa, Via San Zeno 31, 56123 Pisa (Italy). e-mail: concetta@in.cnr.it

Received: 19 March 2019

Accepted: 24 September 2019

Published: 18 December 2019

Keywords: retinitis pigmentosa; low vision; visual BOLD responses; cortical thickness; contrast sensitivity

Citation: Castaldi E, Cicchini GM, Falsini B, Binda P, Morrone MC. Residual visual responses in patients with retinitis pigmentosa revealed by functional magnetic resonance imaging. *Trans Vis Sci Tech.* 2019; 8(6):44, <https://doi.org/10.1167/tvst.8.6.44>
Copyright 2019 The Authors

Purpose: We evaluated the potential of magnetic resonance imaging in identifying signs of cortical visual processing with greater sensitivity than standard ophthalmological measures in patients with retinitis pigmentosa (RP) at advanced stages.

Methods: Eight patients affected with RP with only bare light perception and weak or absent visual evoked potential (VEP) or electroretinogram (ERG) responses to flashes of light were tested. Visual impairment was evaluated by means of psychophysical testing, where patients were asked to discriminate the drifting direction of a contrast modulated grating. Patients underwent magnetic resonance imaging scanning, and the behavioral performance was correlated with both blood oxygenation level-dependent (BOLD) signal elicited by flashes of lights and cortical thickness measured in primary visual area.

Results: Contrast sensitivity to drifting gratings of very low spatial and temporal frequency was greatly impaired, yet measurable in all patients. Weak luminance flashes elicited significant BOLD responses in the striate and extrastriate cortex, despite that the stimuli were not perceived during scanning. Importantly, patients with less severe impairment of contrast sensitivity showed stronger V1 BOLD responses. Striate cortical thickness did not correlate with visual sensitivity.

Conclusions: BOLD responses provide a sensitive and reliable index of visual sparing more than VEPs or ERGs, which are often absent in RP patients. The minimal residual vision can be assessed by optimal visual stimulation in two alternative forced choice discrimination tasks and by BOLD responses. Imaging techniques provide useful information to monitor progressive vision loss.

Translational Relevance: Functional magnetic resonance imaging might be a practical tool for assessing visual sparing, as it is more feasible and sensitive than psychophysical or ophthalmological testing.

Introduction

Visual deficit assessment is typically based on clinical history and ophthalmological measures, such as perimetry, visual acuity, and imaging examination of the retina. Over the last few decades, the development of brain imaging techniques have

equipped the field of neuroscience with progressively more sophisticated and noninvasive methodologies to investigate the human brain. Although limited in number, some studies have applied neuroimaging methods, in particular magnetic resonance imaging (MRI), to reveal structural, functional, and neurochemical changes related to different eye diseases, such as macular degeneration, retinitis pigmentosa

(RP), glaucoma, albinism, and amblyopia (for a review see Ref. 1). The MRI technology allows researchers to relate brain signals acquired with high spatial resolutions (few millimeters) with clinical symptoms and behavioral reports, offering unique opportunities to track the effects of visual deficits on the visual system beyond the eye. This is important for the development of methods that support diagnosis and objectively quantify treatment efficacy.

In this study, we evaluated the added value of functional MRI (fMRI), measuring the blood oxygenation level changes in response to visual stimuli in patients with end-stage RP. RP is a group of hereditary retinal diseases affecting about 1 in 4000 individuals worldwide, which is characterized by the progressive loss of photoreceptors.²⁻⁴ In its initial stages, RP affects the peripheral region (patients develop “tunnel vision” where only the central visual field is preserved); later it gradually extends to the fovea, culminating in complete blindness.

The few fMRI studies on RP described in the literature tested patients with a considerable spared central vision and preserved macular function sufficient to maintain fixation on a small central dot while undergoing retinotopic mapping⁵⁻⁷ or to perform visual discrimination tasks.⁸ These studies showed preserved occipital pole activations in areas retinotopically corresponding to the spared central visual field.⁶⁻⁸ The regions of the primary visual cortex (V1) matching the patients’ scotoma were described as either silent⁷ or remapped to represent stimuli outside the scotoma.⁵ One study showed that the blood oxygenation level-dependent (BOLD) signal can be elicited in the retinotopic representation of the V1 scotoma, but the activity depends on the task, opening the possibility that the origin of these V1 responses lies in the upregulation or the unmasking of feedback projections from extrastriate areas.⁸

These studies focused on the functional reorganization of the occipital cortex in RP patients with partially preserved vision; however, much less is known about the cortical responses at the very end stage of the disease.

To our knowledge, only three studies have attempted to detect visual responses with fMRI in patients with extremely low visual acuity. One study tested a group of RP patients with unspecified genotypes and undetectable visual evoked potentials (VEPs) or electroretinogram (ERG) responses,⁹ and two other studies measured patients affected with Leber congenital amaurosis with either GUCY2D¹⁰ or RPE65 gene mutation and its canine model.¹¹

Although characterized by much earlier onset and subtle physiopathological differences with respect to RP, the retinal dystrophy associated with Leber amaurosis causes profound vision impairments, eventually resulting in no light perception and absent ERG responses^{10,11} like in end-stage RP. Surprisingly, despite the profound visual impairment, these studies reported small but consistent BOLD responses to wide-field flashing or flickering visual stimulation in primary visual areas.⁹⁻¹¹ However, one study reported that patients did not perceive any visual stimulation during the scanning, questioning the functional relevance of these activations.⁹ This opens the question of whether the observed activations were an epiphenomenon associated with paroxysm of neuronal discharge and aberrant retinal-thalamic input not conveying any useful visual information, as observed in animal models¹²⁻¹⁴ or whether they reflected some residual visual input able to generate a BOLD response given the long integration time of the measurement. A third possibility is the involvement of noncone and nonrod photosensitive pathways, such as that of melanopsin-containing intrinsically photosensitive retinal ganglion cells. However, it is not clear whether melanopsin signals can elicit V1 responses at photopic light levels or whether the observed responses in sighted subjects were the consequence of penumbral cone stimulation.¹⁵ Only very high luminance and low-temporal frequency stimuli are able to stimulate the melanopsin-sensitive pathway,¹⁶ and such stimuli were not used in the previously cited studies with visually impaired patients.

MRI has also been used to evaluate whether RP is associated with structural changes of the cortex. The only two studies measuring cortical thickness in primary visual cortex found minor or no differences between RP late-blind patients and controls, possibly due to the substantial preservation of the retinocortical input in these subjects.^{5,17} This is in contrast to the increase of the striate cortical thickness observed in early-blind patients^{18,19} and with the gray matter thickening observed in patients affected with Leber congenital amaurosis caused by a GUCY2D gene mutation.¹⁰ Reduced gray matter volume in the occipital cortex has been detected in more advanced stages of late-onset RP by voxel-based morphometry.²⁰ However, voxel-based morphometry measures reflect the overall volume without providing a direct measure of thickness, which is the most relevant parameter predicting cortical reorganization. Indeed, V1 cortical thickness has been specifically related to the strength of cross-modal responses in the visual

Table 1. Clinical Data of Patients Included in the Experiment

Patient	Sex	Age (years)	Disease Duration (years)	VA logMAR	Full-Field ERGs to Transient Flashes	VEPs to Transient Flashes
S1	M	68	8	>3	SNR < 1	SNR < 1
S2	F	58	17	>3	SNR < 1	SNR < 1
S3	F	51	27	>3	SNR < 1	SNR < 1
S4	M	58	6	>3	N/A	N/A
S5	M	43	25	>3	SNR < 1 (41 Hz)	SNR < 1 (8 Hz)
S6	M	25	20	RE: 2.3 LE: 1.7	SNR > 1 (41 Hz)	SNR > 1 (8Hz)
S7	F	69	25	RE: 1.8 LE: 1.8	SNR > 2 (41 Hz)	N/A
S8	F	50	15	>3	SNR < 1	SNR < 1

VA, visual acuity expressed in logarithm of the minimum angle of resolution (logMAR); SNR, signal-to-noise ratio; N/A, not available; RE, right eye; LE, left eye.

cortex,²¹ independently of the blinding pathology and patient age, and could be the most crucial prognostic predictor of treatment effectiveness.

Overall, despite the unclear origin of BOLD responses in RP patients, on one hand, and the little documented structural changes at the advanced stage of the disease on the other, these studies clearly demonstrate that MRI is a useful tool to unravel functional and structural properties of the visual cortex in the blind, the neural architecture of the visual system, and its plastic reorganization potential that are not reflected by standard clinical measures.

In the present experiment, we studied patients at a very late stage of the disease, with severely impaired visual sensitivity. ERGs and VEP responses were very weak or absent in these patients, who were thereby considered as (near) completely blind. We measured BOLD responses and cortical thickness in V1 and correlated them with the residual visual abilities revealed by visual stimuli created “ad-hoc” in the laboratory. In this way, we asked whether changes detected by MRI techniques can be associated to functionally meaningful residual visual processing.

Methods

Subjects

This study was conducted with a group of eight adult patients (males, $n = 4$; females, $n = 4$; age, 53 ± 14 years) affected with RP with “bare light perception” or “hand motion.” Hand motion is a well-defined metric of visual acuity (see for example Table

1 of Ref. 22) for patients with low vision and was established when the patient was unable to perceive any letter of the chart at any possible distance. Bare light perception, a step lower in the visual acuity scale, was assessed by a light source from a direct ophthalmoscope presented to the four visual field quadrants (superior, inferior, nasal, and temporal). Perception of hand motion or bare light perception was established in all patients before inclusion in the study. Patients had very low or immeasurable monocular logarithm of the minimum angle of resolution (logMAR) visual acuity. Exclusion criteria included deafness, uncontrolled systemic or neurological diseases, pregnancy and presence of metallic joint prostheses, artificial heart valves, pacemakers, metal clips, cochlear implants, or any other metal fragment inside their body.

Subjects’ clinical details are listed in Table 1 and examples of VEPs are shown in Figure 1.

In addition, three subjects (males, $n = 1$; females, $n = 2$; age, 29 ± 3 years old) with normal or corrected to normal vision were recruited to obtain typical psychophysical performance, and another four participants underwent MRI scanning (males, $n = 2$; females, $n = 2$; age, 29 ± 2 years old).

All subjects signed the informed consent in line with the Declaration of Helsinki after being informed about the nature and possible consequences of the study (none in this case). The MRI and the psychophysical protocol of this study were approved by the Ethics Committee of Fondazione Stella Maris (protocol N 11/2012, IRB00003240), which has been

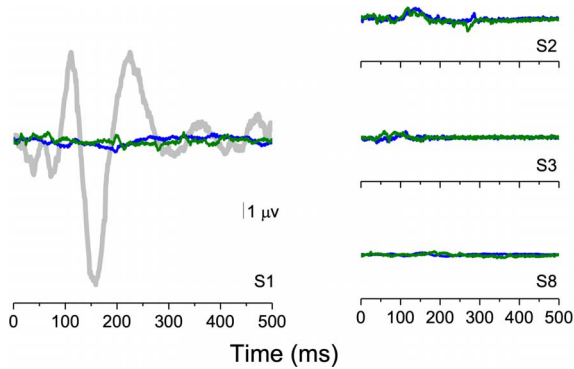


Figure 1. Examples of VEPs responses. (A) The plot shows the transient VEPs in response to a flash for sighted subjects (in gray) and for one subject with no detectable responses (S1, blue and green line corresponding to VEPs recorded from the left and right eye respectively). (B) The plots show examples of VEPs recorded from other subjects (S2, S3, and S8). The temporal frequency of the flash was 1 Hz.

superseded by the Regional Pediatric Ethical Board (IRB 00009689).

ERG, VEP, and Psychophysical Procedure

ERGs were recorded with gold-coated Mylar electrodes positioned in the lower fornix of each eye. The other eye was closed and served as a reference. We also recorded VEPs, with Ag-AgCl electrodes placed 2 cm above theinion (active) and at the vertex. The common ground for all recordings was on the forehead. ERG and VEP signals were amplified (ERG, 100,000-fold; VEP, 50,000-fold), band-pass filtered between 1 to 100 Hz (6 dB/oct), and averaged

on-line over at least 300 periods. The visual stimulus was a strong flash (500 mJ) positioned at about a 20-cm distance from the subject eye and delivered at a frequency of 0.5 Hz for most of the subjects. In three RP patients (S5, S6, and S7) focal ERGs (fERGs) with flashes flickering at 41 Hz were measured, and in two patient (S5 and S6) VEPs were acquired with flashes flickering at 8 Hz.

Vision impairment was further measured in a psychophysical experiment where patients performed a motion direction discrimination task, with a two-alternative forced choice procedure (Fig. 2A). Subjects sat approximately 57 cm in front of a large plasma screen (covering 86×55 degree; Pioneer PDP-501; Pioneer, Saitama, Japan). Stimulus presentation was controlled via a ViSaGe (Cambridge Research Systems, Rochester, UK) 2/5 framestore capable of delivering 12-bit greyscale resolution. Prior to data collection, the monitor was gamma corrected by collecting the photometric values at all luminance levels to ensure a linearized greyscale output. The stimuli were 40-degrees wide contrast-modulated drifting gratings (0.1%–100% Michelson contrast), with a spatial frequency of 0.0625 cpd presented on a gray background (luminance, 180 cd/m^2). Presentation time was abrupt and lasted 0.5 seconds. The grating drifted rightward or leftward at 4 Hz (corresponding to a speed of 64 degrees/s), the subjects were asked to verbally indicate the direction of a drifting grating, and the experimenter recorded the responses by the appropriate key-press.

RP subjects were required to orient their gaze

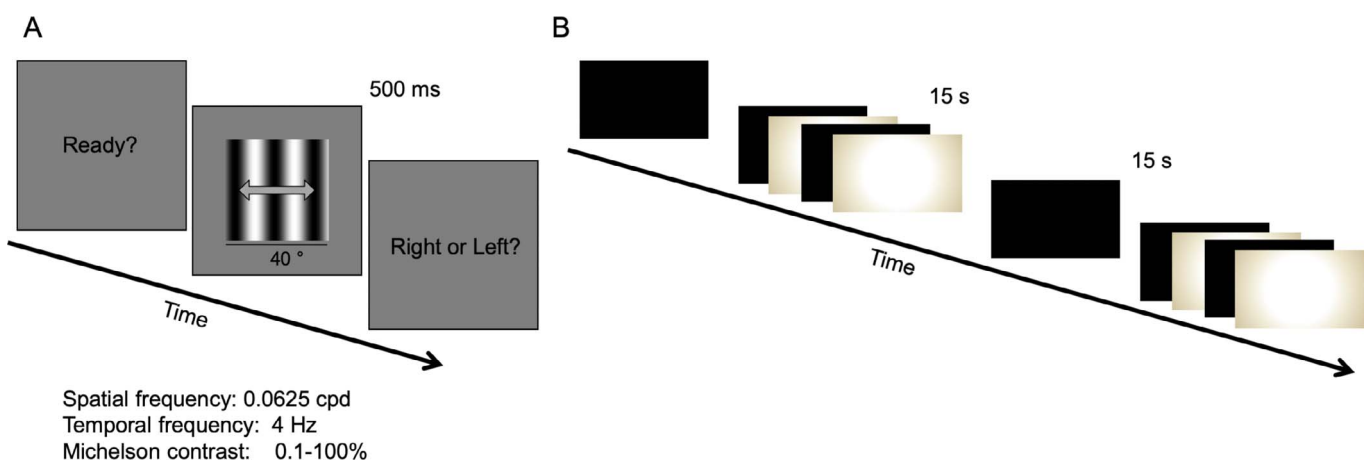


Figure 2. Psychophysical and fMRI paradigms. Examples of the visual stimuli presented in the psychophysical (A) and fMRI (B) experiment. (A) In a two-alternative forced choice motion direction discrimination task, subjects reported the direction of a moving grating (either leftward or rightward). (B) While lying in the scanner with eyes open, participants were exposed to 15-second-long blocks of either complete darkness or flashing lights at 1 Hz. The two different types of blocks alternated six times within a single scanning session.

toward the center of the plasma screen with the help of one experimenter who verified that the head was oriented toward the screen and gave the consent to start the trial. The experimenter delivering the stimulus warned subjects of the upcoming presentation and monitored gaze direction. If presentation occurred during a gaze shift or with eccentric fixation, the trial was discarded. A maximum of five trials per subject were discarded when testing the RP patients and none when testing the sighted group. To become familiarized with the paradigm, RP patients first completed a session with a high-contrast stimulus (60%). Overall, each subject performed 6 sessions of 10 trials.

Subjects' responses were self-paced. This meant that the separation between trials was variable but always longer than 1 second.

After data completion, accuracy was plotted as a function of contrast and a psychometric curve was obtained. Threshold was defined as the contrast at which 75% correct responses were provided.

The same procedure was used with typical observers, and the ratio between the patient thresholds ($THR_{RPsubject}$) and sighted participant thresholds ($THR_{typicals}$) was used as a measure of impairment. We expressed this ratio in dB with this simple transformation:

$$\text{Impairment}_{dB} = -20 \times \log_{10} (THR_{RPsubject} / THR_{typicals}).$$

Magnetic Resonance Imaging

All participants underwent MRI examination in a 1.5T GE scanner (General Electric Healthcare, Chicago, IL). The subjects' eyes were monitored through an infrared camera to assess discomfort symptoms like excessive blinking or squeezing of the eyelids. Head movement was minimized by padding and tape.

MRI data were acquired using a GE 1.5 THD Neuro-optimized System (General Electric Healthcare) fitted with 40 mT/m high-speed gradients. Each session included a whole brain set of anatomical images with T1-weighted contrast. T1-weighted scans were acquired using a FSPGR sequence with repetition time (TR) = 8.4 ms, echo time (TE) = 3.9 ms, flip angle = 8°, and 1-mm isotropic resolution.

Echo Planar Imaging Gradient Echo (EPI-GRE) sequences were used for the fMRI data acquisition (TR = 3000 ms, TE = 35 ms, FOV = 192 × 192 mm, flip angle = 90°, matrix size of 64 × 64, and slice thickness = 3 mm).

During fMRI scanning, 15 seconds of full-field (20° × 30°) flashing stimuli (maximum range, 0.1 cd/m²–60 cd/m² at 1 Hz: 500 ms on and 500 ms off) alternated with 15-second rest periods of dark six times (Fig. 2B). The transition of the flashing stimulus was abrupt, and the stimulus energy had a broad temporal frequency spectrum (energy at low and high temporal frequencies). Stimuli were displayed through liquid crystal goggles equipped with an infrared eye movement camera (at a resolution of 800 × 600, subtending 30° × 22.5° at an apparent distance of 1.5 m, with mean luminance of 30 cd/m²; VisuaStim XGA Resonance Technology, Northridge, CA).

RP subjects performed one anatomical scan and two functional scans, and sighted subjects performed only one anatomical and one functional scan. Subjects were instructed to keep their eyes open. After the MRI scan, we questioned subjects about their visual perception during the scanning. No RP patients reported any perception of light flashes.

Data Analysis

Imaging data were analyzed with Brain Voyager Qx (version 2.8; Rainer Goebel, Brain Innovation B.V., Maastricht, The Netherlands). Anatomical images were spatially normalized using the Talairach and Tournoux atlas.

Rigid body motion parameters (three translations and three rotations) were calculated and compared across groups (Fig. 3). Comparing the maximum range of motion across the two groups did not yield to significant differences ($t[18] = 0.5$, $P = 0.6$), and the amount of motion never exceeded the voxel size, allowing us to include the functional dataset in the analysis. Functional data were preprocessed to compensate for systematic slice-dependent differences in acquisition time (using cubic spline), three-dimensional motion correction (using Trilinear/Sync interpolation realigning data to the first volume of the first scan), and temporal filtering (high-pass filter general linear model [GLM] with Fourier basis set, including linear trend, with two cycles). No spatial smoothing was used.

We analyzed the data with a multistudy, multi-subject GLM with a box-car regressor corresponding to the flashing light blocks. The regressor was convolved with the canonical hemodynamic response function and contrasted against the baseline (dark blocks). To identify the visual areas showing light-evoked responses in blind subjects, we performed cortex-based alignment between the RP patients and a sighted subject who underwent standard retinotopic

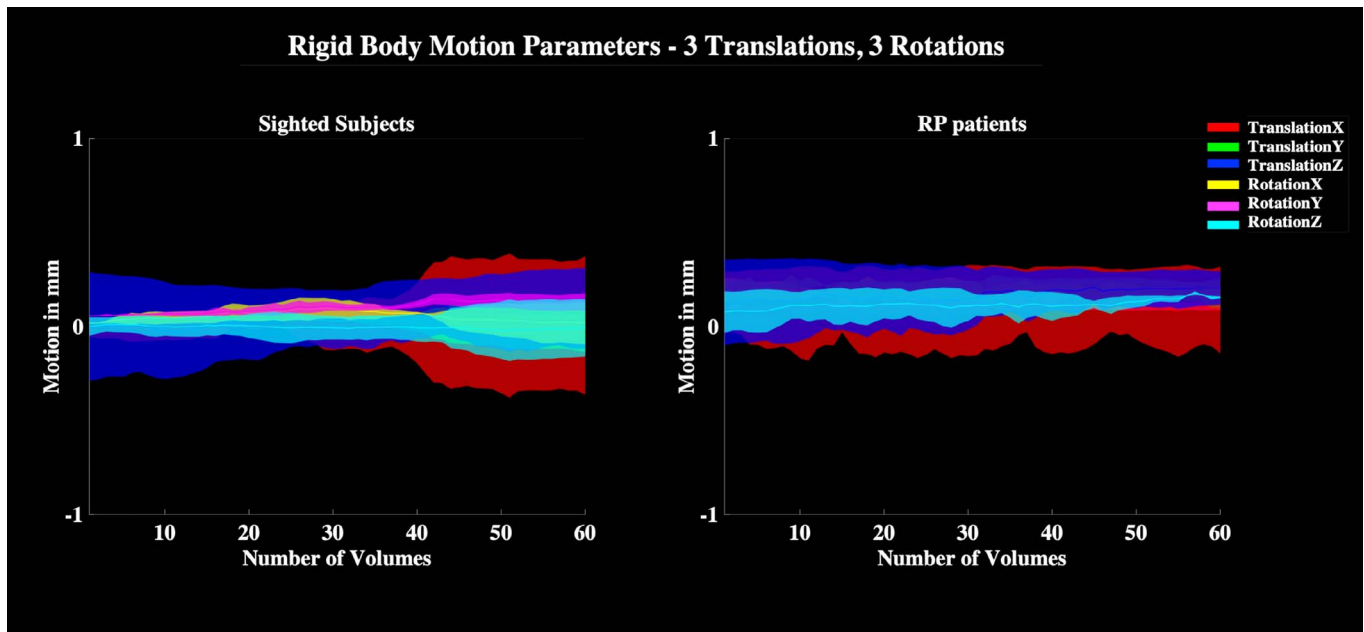


Figure 3. Motion parameters. Rigid body motion parameters (in mm, three translations and three rotations) as a function of the number of volumes included in the EPI time series for the sighted (*left*) and RP (*right*) group. Different motion components are associated with different colors, as specified in the legend, and shadows represent the standard error of the mean across subjects for every motion direction.

mapping (for stimuli description see Ref. 23). This procedure aligns the brains of a group by using the gyral/sulcal folding pattern of the cortex. We displayed the statistical map obtained from the GLM in blind participants onto the aligned surface where the boundaries of the visual areas were traced. To evaluate the fMRI time course and the functional significance of the activation, in each patient we defined a region of interest (ROI) for each hemisphere along the calcarine sulcus starting from the most occipital pole along the sulcus for 3 cm, representing about 20 degrees of visual space.^{24,25} We extracted the time course from the individual ROIs, and we averaged them across repetitions (epoch-based event related averaging). We also evaluated the amplitude and phase (the latter being a measure of the hemodynamic delay) of the response, by performing an fast Fourier transform on the time course (before averaging).

Moreover, beta values were extracted from the individual ROIs, and the signal extracted from the hemisphere showing the strongest response was correlated with the visual impairment quantified by means of the motion direction discrimination task. We performed this analysis only on the primary visual area because this area shows clear anatomical landmarks, allowing for relatively certain border

identification at the single subject level, whereas other higher order regions are more variably located across sulci and gyri. Cortical thickness was also calculated and correlated with visual impairment, as measured by the psychophysical task.

Results

Given the recruitment criteria of bare light or hand-motion perception (see Methods), the motion direction discrimination task was tiring and difficult for many patients. Nevertheless, the measurements were reliable, although RP subjects' contrast threshold was much higher with respect to sighted participants (Fig. 4).

In the scanner, we measured BOLD signals in response to a sequence of flashes of lights (1 Hz). In normally sighted subjects, flashes of light extensively activated a large network of visual areas, including occipital, temporal, and parietal regions ($P < 0.005$, corresponding to false discovery rate q-value of < 0.05 ; Fig. 5A). Surprisingly, despite the fact that RP patients never reported seeing the weak flashes (60 cd/m^2), we observed some light-evoked BOLD responses in similar areas as in typical subjects (Fig. 5B) ($P < 0.05$, uncorrected). Most activations were still detectable at a more conservative threshold (Fig.

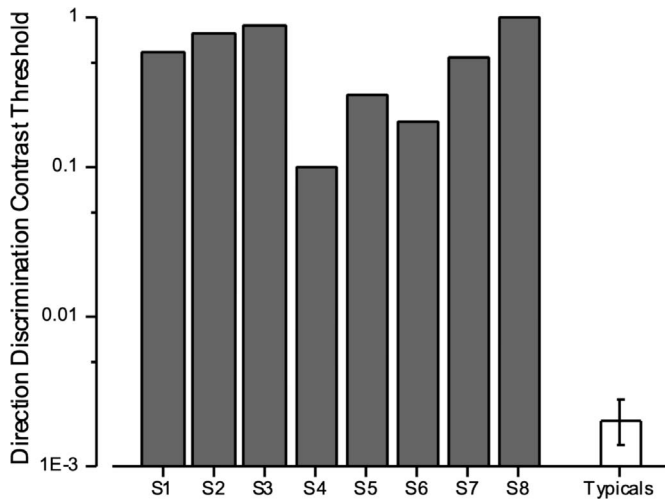


Figure 4. Contrast thresholds at which 75% correct responses during the motion direction discrimination task were provided. Bars show contrast thresholds in RP (S1–S8, gray bars) and sighted subjects (white bar, mean \pm SD). In line with the inclusion criteria of bare light perception, RP thresholds were extremely high with respect to sighted participants.

5C) (average $P < 0.01$, uncorrected). This finding, although surprising given the absence of VEP responses to stronger flashes than those used in the fMRI experiment, is consistent with previous reports of spared BOLD activation in the occipital, temporal, and parietal areas of patients with advanced stage RP.⁹ Projecting the activations onto a surface-based aligned brain of a sighted subject who underwent standard retinotopic mapping, allowed us localize the activation foci. These fell within the calcarine sulcus at the foveal representation of V1, in the lateral occipital and medio-temporal sulcus within the lateral occipital (LOC) and medio temporal (MT) complex, posteriorly in the fusiform/collateral sulcus at the level of V4 and along the dorsal stream mainly at the level of V3AB/V7 (Fig. 6) ($P < 0.05$, uncorrected). To characterize the properties of these functional responses, we further analyzed the fMRI time course. For each subject, we measured the fMRI response (% BOLD signal) in an anatomically defined ROI positioned along the calcarine sulcus, approximately corresponding to the first 20 degrees of visual space. Figure 7A shows the fMRI time course as a function of time for both the RP and the sighted group. The fMRI response in the RP group was overall lower with respect to the sighted group, although not visibly delayed (Fig. 7A), as can be observed from the averaged time course synchronized with the stimulus onset (Fig. 7B). All subjects had weaker responses, as shown in the polar plots representing the amplitude

and phase of the fMRI responses in the two groups (Fig. 7C, 7D); there was a large difference in the amplitude of the fMRI response between groups (mean amplitude for the sighted group = 0.8 ± 0.2 , mean amplitude for the RP group = 0.3 ± 0.1) but only a minor difference in phase (mean phase for the sighted group = 51 ± 17 , mean phase for the RP group = 66 ± 48).

Next, to determine the functional role of the observed activations, we calculated the average beta value in these ROIs and correlated these values with patients' performance in the motion direction discrimination task. The subjects who performed the motion direction discrimination task with greater (although much impaired) sensitivity also showed higher BOLD responses in the calcarine sulcus (Fig. 8A). Interestingly, although a significant correlation ($r = 0.73$, $P < 0.039$) was observed between BOLD response and contrast sensitivity, we failed to observe a significant correlation between visual impairment and the cortical thickness for the same V1 ROI (Fig. 8B) ($r = 0.46$, $P = 0.24$), despite the fact that the RP group showed a significantly thinner V1 with respect to the sighted group (Median patients = 1.7, Median sighted = 3.3, Mann-Whitney $U = 32$, $P = 0.004$). However, this difference might be, in part, related to the age difference between groups (the sighted group was younger than the RP group, Mann-Whitney $U = 4$, $P = 0.048$).

Discussion

In the current experiment, we demonstrated that fMRI can detect signals of spared visual processing with higher sensitivity than other objective and quantitative measures used for standard ophthalmological testing. A recent study on patients with Stargardt disease showed that electrophysiological responses were strongly correlated with activation of the primary visual cortex and concluded that evaluation of neural reorganization can be performed considering ERG responses only.²⁶ However, reliable ERG responses might not be detectable in patients affected by retinal dystrophies at the very late stage,^{9,11} limiting the diagnostic use of this technique. In our sample of participants (RP patients at a very advanced stage of the disease and with severely impaired visual sensitivity or bare light perception), only one patient showed a reliable ERG response. Nevertheless, we were able to measure above-chance motion discrimination performance in all patients, demonstrating that visual processing remains possible

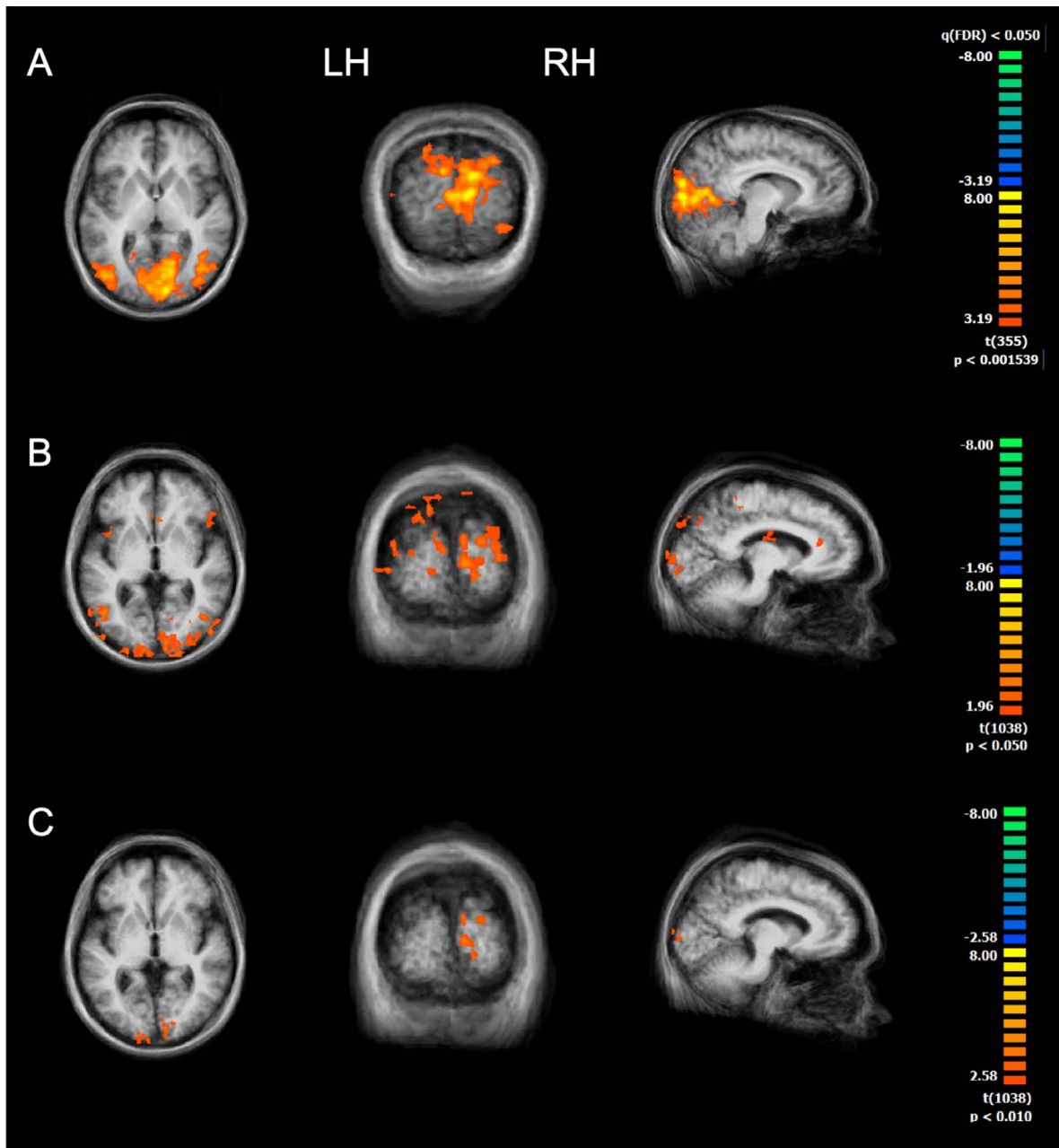


Figure 5. BOLD response to flashing lights. Cortical activity elicited by flashing stimuli in (A) four sighted subjects and in (B, C) eight RP patients (B and C come from the same data set but at different thresholds). Although the cortical activity was vastly reduced with respect to sighted subjects, some responses were detectable in occipital, parietal, and ventral visual cortices of RP patients at $P < 0.05$ (B) and most of these regions remained active even when displaying statistical activation maps at a more conservative threshold ($P < 0.01$, C). Images comes from similar slices of the brain (A) $x = 8, y = -88, z = 4$; (B and C) $x = -10, y = -88, z = 1$.

(for a specific class of visual stimuli) even in this advanced stage of the disease and can support perception. The stimuli were obtained by using long exposure time, very large visual field, very low spatial and temporal frequencies, and accurately linearized display, eliminating all possible luminance cues normally introduced with high-contrast gratings,

which are all conditions achieved in controlled laboratory settings, not easily generalizable to the clinical settings. In addition, the task was difficult for the patients and required many hours of observation, making it not feasible for a clinical diagnostic tool. The fMRI testing, on the other hand, is more comfortable and easier for the patient, making it

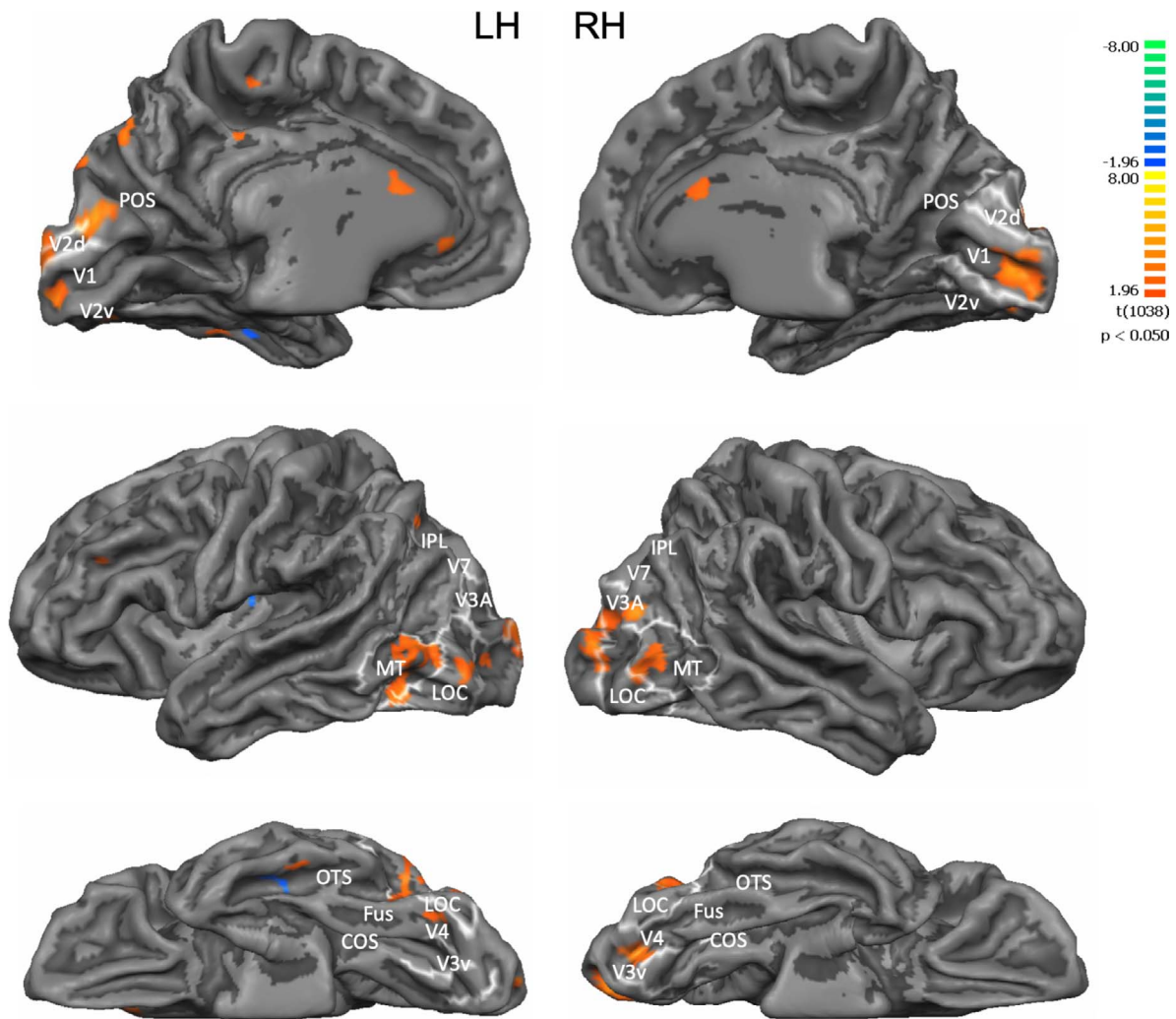


Figure 6. BOLD response to flashing lights in RP patients. Results from the multistudy, multisubject GLM when displaying the activation map onto a surface-based aligned brain of a seeing subject who underwent standard retinotopic mapping. The (A) medial, (B) lateral, and (C) inferior views of the brain are shown and *yellow outlines* mark borders of the retinotopically defined visual areas. Anatomically, activity was detected in (A) medial view: striate and extrastriate cortex, parieto-occipital sulcus; (B) lateral view: middle temporal gyrus, lateral occipital sulcus, inferior temporal sulcus, and (C) inferior view: occipitotemporal sulcus, fusiform gyrus/collateral sulcus. COS, collateral sulcus; Fus, fusiform gyrus; IPL, inferior parietal lobe; LOC, lateral occipital complex; OTS, occipitotemporal sulcus; POS, parieto-occipital sulcus.

more feasible for clinical use. Although fMRI revealed BOLD responses to weak flashes in multiple cortical areas, electrophysiological responses to strong flashes were absent or very weak in nearly all our patients. The higher sensitivity of BOLD signals with respect to electrophysiological measures most likely depends on the nature of the signal itself. Indeed, the fMRI signal integrates bottom-up and top-down sources of activity over a long time period. Therefore, the signal readout from a given region reflects the integration of multiple sources of neural activity over a time interval of several seconds. Interestingly, BOLD responses correlated with the

degree of visual sparing measured with our ad-hoc motion direction discrimination task, suggesting that they measure the spared functional activity, thereby, validating the technique. Importantly, we can rule out the possibility that higher attentional load might explain the BOLD responses observed, given that the light flashes were never perceived and participants were not asked to perform any task.

Although the correlation with the psychophysics strongly suggests that the BOLD response is related to the residual vision, the neuronal origins of the BOLD response is at present not clear. It has been shown that melanopsin-sensitive ganglion cells can

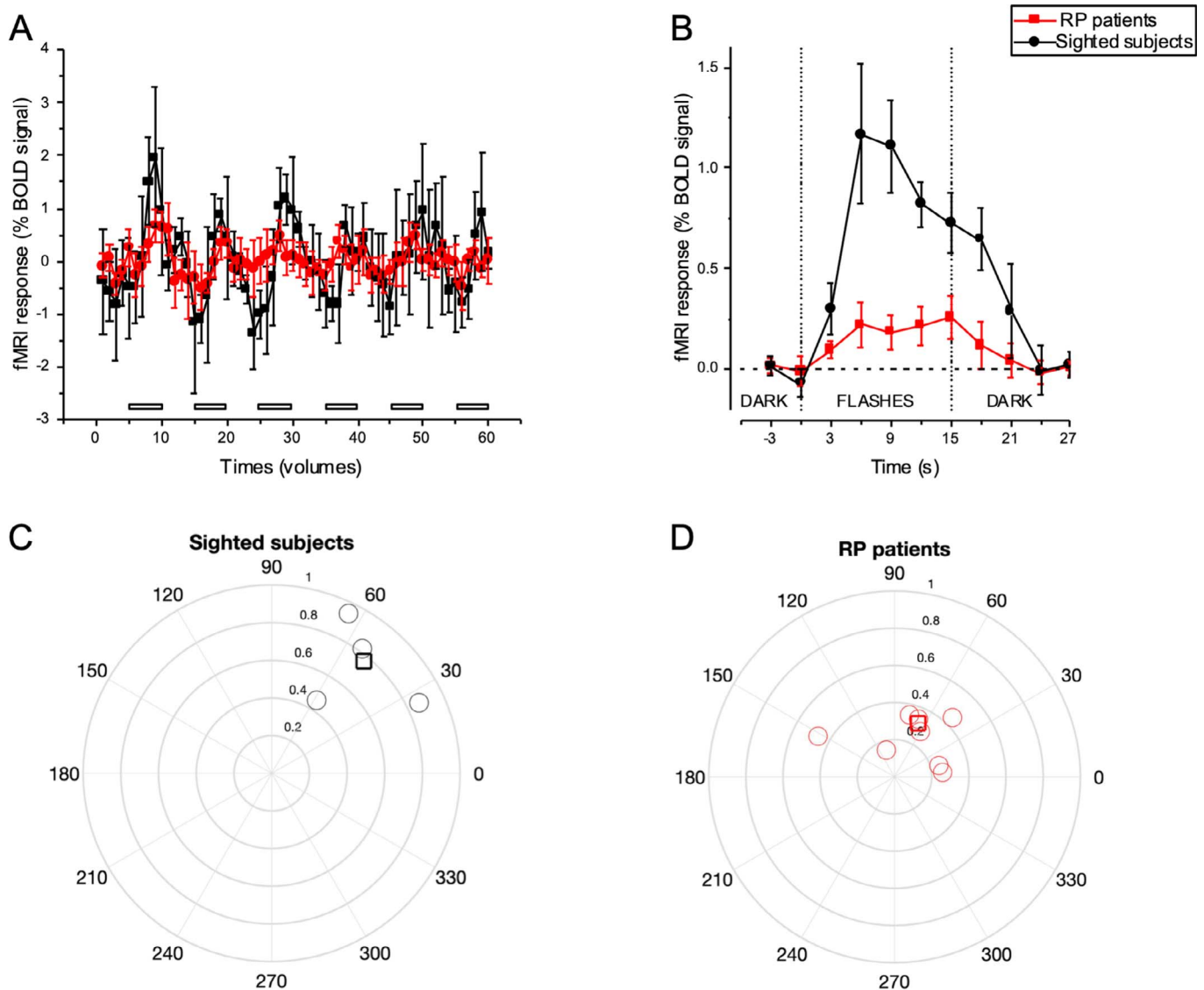


Figure 7. fMRI time course and its properties. (A) fMRI response as a function of time for the RP (red) and sighted (black) group shown for the entire length of the run and averaged across periods of repetition (right). Onsets and offsets of the flashing light stimulation periods during the run are demarcated by the gray horizontal bars. (B) Averaged of the time course shown in (A) synchronized with every stimulus onset. Vertical dashed lines mark stimulus onset and offset time. (C and D) Polar plots for the sighted (C) and RP group (D) showing amplitude and phase of the fMRI response. Circles represent individual subjects, while the thick lined squares represent the average across subjects. The distance between every point and the origin represents the amplitude of the fMRI response, and the angle represents the phase. Overall the fMRI response in the RP group was lower with respect to the sighted group but had similar hemodynamic response (phase).

elicit BOLD responses in V1 and mediate perception.¹⁶ These cells are most likely preserved in RP, and we cannot exclude that they might have partially contributed to the observed BOLD activations. However, these cells are stimulated by much stronger luminance levels than that used in the scanner, making their contribution unlikely. Moreover the melanopsin-sensitive cell responses are very slow and sustained²⁷ and can hardly mediate motion perception

in our psychophysical test. Most likely the cortical responses observed are mediated by the residual cone or rod functioning. This is consistent with the good psychophysical and BOLD responses in the two subjects (S6 and S7) that had some residual cone functioning, as demonstrate by the presence of ERG signals at 41 Hz. Nevertheless, to empirically exclude a melanopsin contribution, future studies should directly compare the perceptual experience and visual

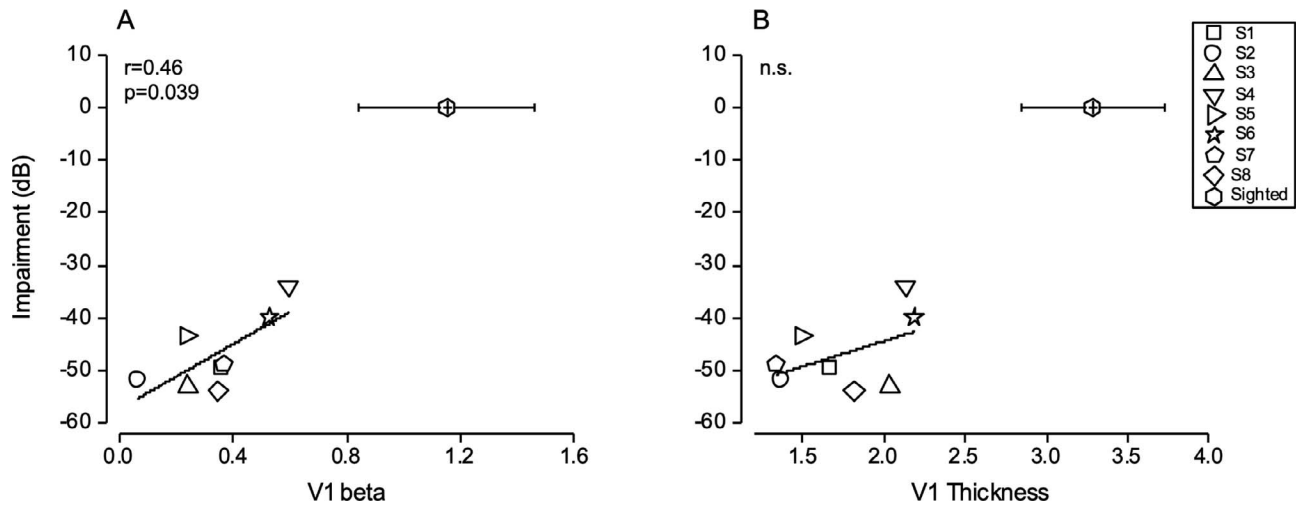


Figure 8. Correlation analyses. Visual impairment (expressed in dB) as a function of (A) beta-values and (B) cortical thickness measured along the calcarine sulcus. Despite the fact that flashing lights were not perceived during the scanning, patients with higher beta values showed a better, yet highly impaired performance when determining the direction of a drifting grating during the psychophysical test. Cortical thickness did not predict the degree of visual impairment in our sample of subjects. Mean values for sighted subjects are shown to provide references, but they were not included in the correlation analyses.

BOLD responses elicited by selective stimulation of melanopsin and long, medium, and short wavelength sensitive (LMS) cone pathways in RP patients.

The present study, in agreement with previous results,⁹⁻¹¹ indicates that some visual information reaches the cortex of patients with extremely low visual sensitivity due to retinal dystrophies. Yet, despite the fact that visual BOLD responses were detected in several brain regions, participants never reported seeing flashing lights. This is surprising given the significant correlation discussed above. The presence of BOLD responses argues against the idea of retinal or thalamic suppression of flashes and suggests that there may be cortical gating mechanisms suppressing vision. The residual visual information reaching the cortex can be aberrant, noisy, delayed, and not so useful for reliable visual perception.²⁸ Indeed, animal models of retinal degeneration described aberrant rhythmic and spontaneous ganglion cell hyperactivity following photoreceptor loss, triggered by the coupled activity of amacrine and bipolar cells,^{13,14} and this aberrant activity was shown to propagate up to higher brain regions.¹² If aberrant visual information is actively suppressed in RP patients, then it would be important to establish at which level of cortical processing such suppression arises. In our experiment, we observed BOLD responses within and well beyond the primary visual cortex, potentially suggesting that the visual input travelled all the way up the visual hierarchy and making it unlikely that the visual input was sup-

pressed locally within V1. It is possible that V1 retained the capability to respond to visual inputs but that the flashing lights shown in the scanner were not sufficiently strong to elicit a conscious perception. Thus, the visual stimulation conveyed by flashing lights and reaching V1, although potentially useful, was possibly too weak, labeled as “aberrant” by the visual cortex, and thus actively suppressed by extrastriate areas. The primary visual area receives feedback projections from several hierarchically higher visual regions, such as V2, V3, V5, the lateral occipital complex, and the intraparietal sulcus.²⁹ Masuda et al.⁸ suggested that in sighted subjects the feedback projections to V1 are gated by the lateral geniculate nucleus, which allows extrastriate areas to interact with the incoming signal only if it is meaningful and reliable (e.g., sufficiently contrasted and not noisy). In blind patients, the dysfunctional gating mechanisms might allow the feedback projections to more strongly interact with the abnormal input signal. The lack of visual perception in the presence of BOLD responses observed in our data suggests that the nature of the interaction between extrastriate feedback projections and incoming noisy or weak input might be inhibitory.

Suppressing the aberrant visual activity might be beneficial to prompt a faster reorganization of the deprived visual cortex, which can be recruited for processing information from other sensory modalities, such as touch or audition. Cross-modal plasticity has been extensively described in early blind people

but also when blindness occurred in adulthood following a variety of pathologies.^{30–32} Previous fMRI studies in RP and Leber Congenital Amaurosis (LCA) patients showed stronger tactile and auditory responses in the primary visual cortex in patients with more severe visual impairment,^{10,33} suggesting that cross-modal reorganization can gradually occur also following retinal dystrophies (for a recent review see Ref. 34). In a separate work by our group, we found that RP patients with sparing of the central visual field have increased visual plasticity, stronger in patients with greater deficits, suggesting that cortical gating might be active throughout the evolution of the disease³⁵ and it might be the consequence of cross-modal (or maladaptive) plasticity.

Although active suppression of visual activity can potentially favor cross-sensory plasticity, at the same time it can reduce the effectiveness of vision restoration therapies, blocking the conscious processing of artificial vision. In a previous experiment, we measured BOLD responses to flashing lights in RP participants before and after implantation with the Argus II retinal prosthesis.⁹ We observed increased BOLD responses after the surgery in V1, V2, and V3 cortices; however, higher order areas, such as MT, LOC, and intraparietal sulcus (IPS), showed stronger activation before the surgery. Based on these observations, we hypothesized that before the surgery, higher order areas were hampering the visual signals in early visual areas and only extensive training with artificial vision gradually reduced the suppressive activity of these areas, while strengthening the signal processed in earlier areas at the same time. It would be important to establish whether inhibiting the suppressive extrastriate signals (for example by transcranial magnetic stimulation (TMS) pulses over associative regions contextually to the behavioral visual training) increases the effectiveness of the prosthesis or accelerates the visual restoration process.

Cortical thickness is another parameter considered a predictor of treatment efficacy, as it can reflect the degree of cross-modal reorganization. Indeed, one previous study reported that blind patients with thicker V1 showed stronger auditory responses in this area.²¹ Cortical thickness changes in visual areas following visual loss have been extensively described in the literature, although the effects are not always in the same direction. Some studies reported cortical thickness increases, especially in congenitally blind individuals and in patients affected by LCA,^{10,18,19,36,37} whereas some

others reported cortical thinning, especially in older patients with progressive retinal diseases, such as macular degeneration or retinal damage related to end-stage glaucoma.^{19,38–41} The only two studies in late-onset RP patients (with some residual vision) reported no or minor changes in V1 cortical thickness.^{5,17} In the current study, we observed thinner V1 in RP patients with respect to the group of sighted subjects (about 1.6-mm difference). However, we cannot establish whether this thinning is related to disuse atrophy or to physiological aging, given that our sighted subjects were not matched for age to the patient group. Yet, the lack of correlation between cortical thickness in V1 and visual impairment does not support the atrophy interpretation. This is consistent with the previously reported independency between these two factors at the early stage of the disease and extends it to the advanced stages of the disease.

Overall, this experiment underlines the importance of exploiting the high sensitivity of imaging techniques for the evaluation of residual vision in visually impaired patients. fMRI might become a practical tool for the routine assessment of visual sparing, which is more feasible than long and difficult psychophysical testing, and it may provide a unique possibility to advance our understanding of ophthalmologic diseases. The advancement of our knowledge of brain reorganization by functional imaging may be fundamental to characterize treatment effectiveness during progressive vision loss caused by disease.

Acknowledgments

We thank Michela Tosetti for her assistance in scanning volunteers, Francesca Tinelli for facilitating and organizing patients participation to the study, and Roberto Arrighi for assistance during the psychophysical testing.

This research received funding from Fondazione Roma under the grants for Biomedical Research RP call for proposals 2013 (<http://www.fondazioneroma.it/it/index.html>, <http://wf-fondazioneroma.cbim.it/>), project title Cortical Plasticity in Retinitis Pigmentosa: an Integrated Study from Animal Models to Humans and from the European Research Council under the European Union's Horizon 2020 research and innovation program (grant agreement no. 801715, PUPILTRAITS).

Disclosure: **E. Castaldi**, None; **G.M. Cicchini**, None; **B. Falsini**, None; **P. Binda**, None; **M.C. Morrone**, None

References

1. Brown HDH, Woodall RL, Kitching RE, Baseler HA, Morland AB. Using magnetic resonance imaging to assess visual deficits: a review. *Ophthalmic Physiol Opt.* 2016;36:240–265.
2. Hamel C. Retinitis pigmentosa. *Orphanet J Rare Dis.* 2006;11:40.
3. Hartong DT, Berson EL, Dryja TP. Retinitis pigmentosa. *Lancet.* 2006;368:1795–1809.
4. Herse P. Retinitis pigmentosa: visual function and multidisciplinary management. *Clin Exp Optom.* 2005;88:335–350.
5. Ferreira S, Pereira AC, Quendera B, Reis A, Silva ED, Castelo-Branco M. Primary visual cortical remapping in patients with inherited peripheral retinal degeneration. *Neuroimage Clin.* 2017;13:428–438.
6. Goesaert E, Van Baelen M, Spileers W, Wagemans J, Op de Beeck HP. Visual space and object space in the cerebral cortex of retinal disease patients. *PLoS One.* 2014;9:e88248.
7. Ritter M, Hummer A, Ledolter A, Holder G, Windischberger C, Schmidt-Erfurth U. Correspondence between retinotopic cortical mapping and conventional functional and morphological assessment of retinal disease. *Br J Ophthalmol.* 2019;103:208–215.
8. Masuda Y, Horiguchi H, Dumoulin SO, Furuta A, Miyauchi S, Nakadomari S, Wandell BA. Task-dependent V1 responses in human retinitis pigmentosa. *Invest Ophthalmol Vis Sci.* 2010;51:5356–5364.
9. Castaldi E, Cicchini GM, Cinelli L, Biagi L, Rizzo S, Morrone MC. Visual BOLD response in late blind subjects with Argus II retinal prosthesis. *PLoS Biol.* 2016;14:e1002569.
10. Aguirre GK, Butt OH, Datta R, et al. Postretinal structure and function in severe congenital photoreceptor blindness caused by mutations in the GUCY2D gene. *Invest Ophthalmol Vis Sci.* 2017;58:959–973.
11. Aguirre GK, Komaromy AM, Cideciyan AV, et al. Canine and human visual cortex intact and responsive despite early retinal blindness from RPE65 mutation. *PLoS Med.* 2007;4:e230.
12. Ivanova E, Yee CW, Baldoni R, Sagdullaev BT. Aberrant activity in retinal degeneration impairs central visual processing and relies on Cx36-containing gap junctions. *Exp Eye Res.* 2016;150:81–89.
13. Trenholm S, Awatramani GB. Origins of spontaneous activity in the degenerating retina. *Front Cell Neurosci.* 2015;9:277.
14. Zeck, G. Aberrant activity in degenerated retinas revealed by electrical imaging. *Front Cell Neurosci.* 2016;10:25.
15. Spitschan M, Datta R, Stern AM, Brainard DH, Aguirre GK. Human visual cortex responses to rapid cone and melanopsin-directed flicker. *J Neurosci.* 2016;36:1471–1482.
16. Spitschan M, Bock AS, Ryan J, Frazzetta G, Brainard DH, Aguirre GK. The human visual cortex response to melanopsin-directed stimulation is accompanied by a distinct perceptual experience. *Proc Natl Acad Sci U S A.* 2017;114:12291–12296.
17. Cunningham SI, Shi Y, Weiland, JD, et al. Feasibility of structural and functional MRI acquisition with unpowered implants in Argus II retinal prosthesis patients: a case study. *Transl Vis Sci Technol.* 2015;4:6.
18. Bridge H, Cowey A, Ragge N, Watkins K. Imaging studies in congenital anophthalmia reveal preservation of brain architecture in “visual” cortex. *Brain.* 2009;132:3467–3480.
19. Park HJ, Lee JD, Kim EY, et al. Morphological alterations in the congenital blind based on the analysis of cortical thickness and surface area. *NeuroImage.* 2009;47:98–106.
20. Machado A, Carvalho Pereira A, Ferreira F, et al. Structure–function correlations in retinitis pigmentosa patients with partially preserved vision: a voxel-based morphometry study. *Sci Rep.* 2017;7:11411.
21. Aguirre GK, Datta R, Benson NC, et al. Patterns of individual variation in visual pathway structure and function in the sighted and blind. *PLoS One.* 2016;11:e0164677.
22. Bach M, Wilke M, Wilhelm B, Zrenner E, Wilke R. Basic quantitative assessment of visual performance in patients with very low vision. *Invest Ophthalmol Vis Sci.* 2010;51:1255–1260.
23. Castaldi E, Frijia F, Montanaro D, Tosetti M, Morrone MC. BOLD human responses to chromatic spatial features. *Eur J Neurosci.* 2013;38:2290–2299.
24. Benson NC, Butt OH, Datta R, Radoeva PD, Brainard DH, Aguirre GK. The retinotopic organization of striate cortex is well predicted

- by surface topology. *Curr Biol.* 2012;22:2081–2085.
25. Schira MM, Tyler CW, Rosa MG. Brain mapping: the (un)folding of striate cortex. *Curr Biol.* 2012;22:R1051–R1053.
 26. Melillo P, Prinster A, Di Iorio V, et al. Visual cortex activation in patients with Stargardt disease. *Invest Ophthalmol Vis Sci.* 2018;59:1503–1511.
 27. Dacey DM, Liao HW, Peterson BB, et al. Melanopsin-expressing ganglion cells in primate retina signal colour and irradiance and project to the LGN. *Nature.* 2005;433:749–754.
 28. Stasheff SF. Clinical impact of spontaneous hyperactivity in degenerating retinas: significance for diagnosis, symptoms, and treatment. *Front Cell Neurosci.* 2018;12:298.
 29. Muckli L, Petro LS. Network interactions: non-geniculate input to V1. *Curr Opin Neurobiol.* 2013;23:195–201.
 30. Bavelier D, Neville HJ. Cross-modal plasticity: where and how? *Nat Rev Neurosci.* 2002;3:443–452.
 31. Lewis LB, Saenz M, Fine I. Mechanisms of cross-modal plasticity in early-blind subjects. *J Neurophysiol.* 2010;104:2995–3008.
 32. Sathian K, Stilla R. Cross-modal plasticity of tactile perception in blindness. *Restor Neurol Neurosci.* 2010;28:271–281.
 33. Cunningham SI, Weiland JD, Bao P, Lopez-Jaime GR, Tjan BS. Correlation of vision loss with tactile-evoked V1 responses in retinitis pigmentosa. *Vision Res.* 2015;111:197–207.
 34. Castaldi E, Lunghi C, Morrone MC. Neuroplasticity in adult human visual cortex. *arXiv.* 2019:1905.02405.
 35. Lunghi C, Galli Resta L, Binda P, et al. Visual cortical plasticity in retinitis pigmentosa. *Invest Ophthalmol Vis Sci.* 2019;60:2753–2763.
 36. d’Almeida OC, Mateus C, Reis A, Grazina MM, Castelo-Branco M. Long term cortical plasticity in visual retinotopic areas in humans with silent retinal ganglion cell loss. *NeuroImage.* 2013;81:222–230.
 37. Jiang J, Zhu W, Shi F, et al. Thick visual cortex in the early blind. *J Neurosci.* 2009;29:2205–2211.
 38. Bogorodzki P, Piatkowska-Janko E, Szaflik J, Szaflik JP, Gacek M, Grieb P. Mapping cortical thickness of the patients with unilateral end-stage open angle glaucoma on planar cerebral cortex maps. *PLoS One.* 2014;9:e93682.
 39. Burge WK, Griffis JC, Nenert R, et al. Cortical thickness in human V1 associated with central vision loss. *Sci Rep.* 2016;6:23268.
 40. Prins D, Plank T, Baseler HA, et al. Surface-based analyses of anatomical properties of the visual cortex in macular degeneration. *PLoS One.* 2016;11:e0146684.
 41. Yu L, Xie B, Yin X, et al. Reduced cortical thickness in primary open-angle glaucoma and its relationship to the retinal nerve fiber layer thickness. *PLoS One.* 2013;8:e73208.